

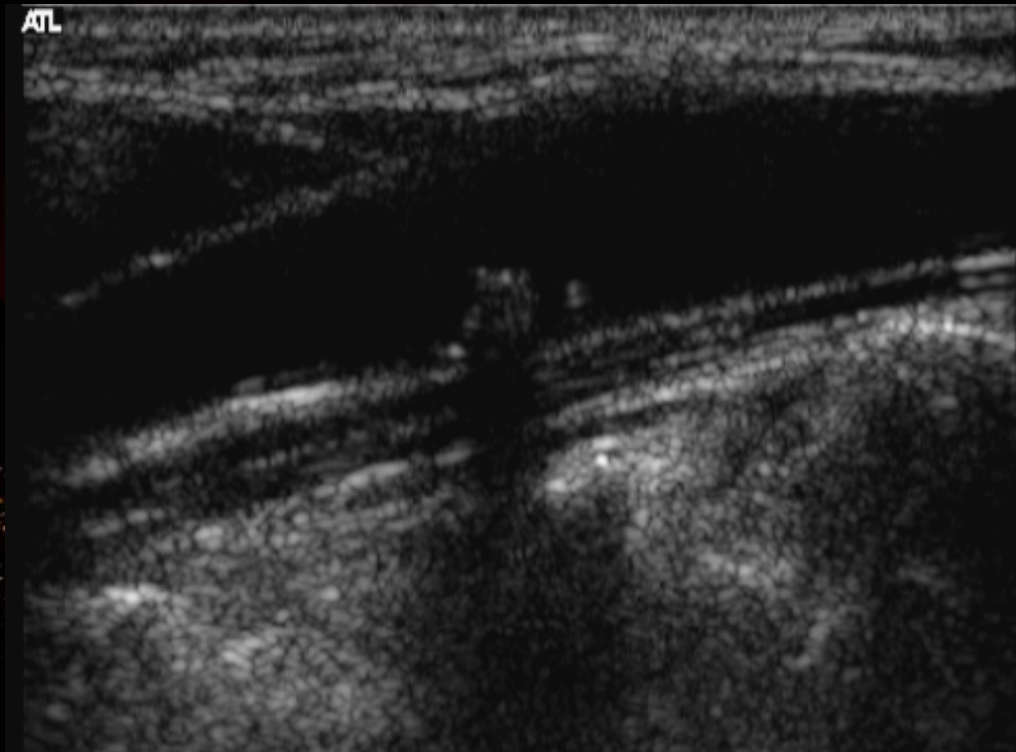


# **How I Explore Carotid Artery Stenosis**

**Donald B Reid**  
**Wishaw Hospital, Scotland**

**MEET 2008**

# Ultrasound



# ICAROS

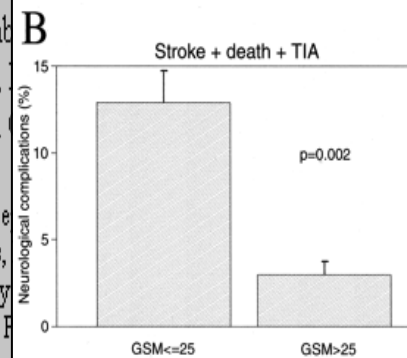
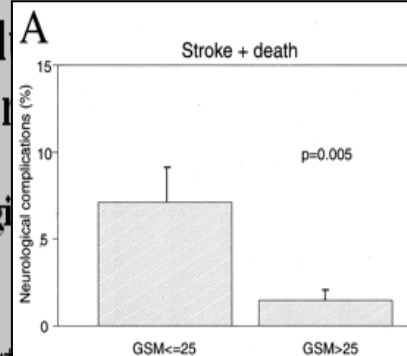
*Circulation*. 2004;110:756-762

## Carotid Plaque Echol Stroke in Carotid Ste

### The Imaging in Carotid Angi Study

Giorgio M. Biasi, MD, FRCS; Albert  
Gaetano Deleo, MD; Stefania Galim  
Andrew N. Nicolaides, MS, FRCS;  
Donald B. Reid, MD, FRCS; Maria

From the Division of Vascular Surgery, De  
A.F., G.D., P.M.) and Section of Statistics,  
Biotechnologies (S.G., M.G.V.), University  
Hospital, Milan, Italy (G.M.B., A.F., G.D., F  
T.D.D.); Corvix Institute of Neurology, Phoenix



AMERICAN HEART ASSOCIATION

k of

ROS)

MD;

re (G.M.B.,

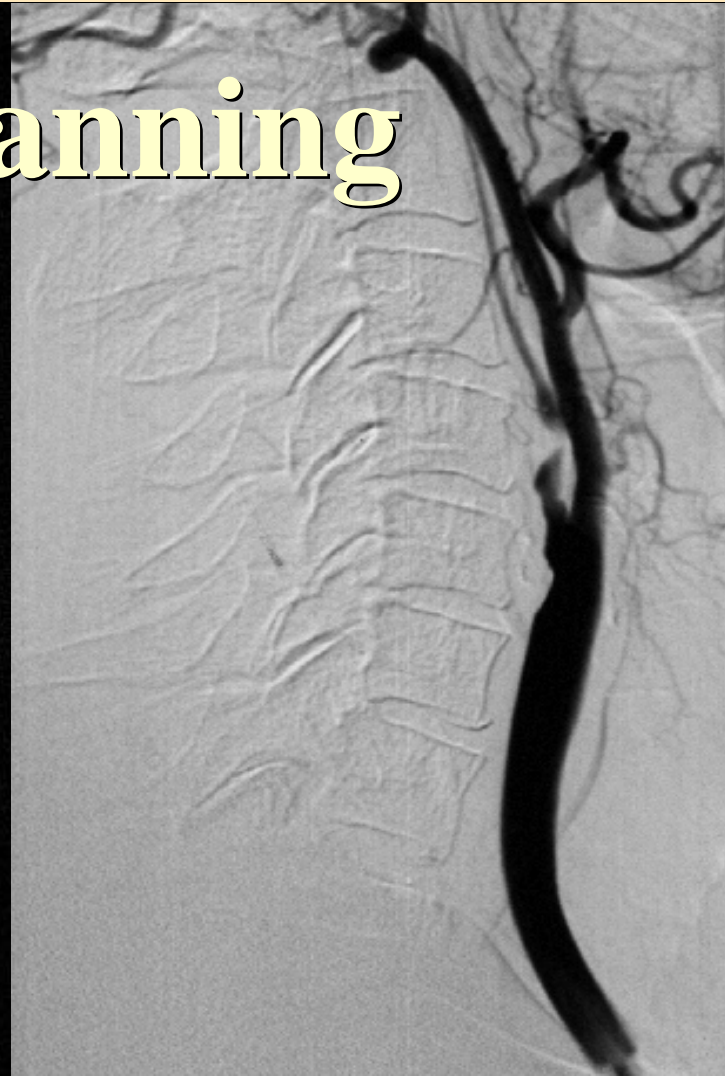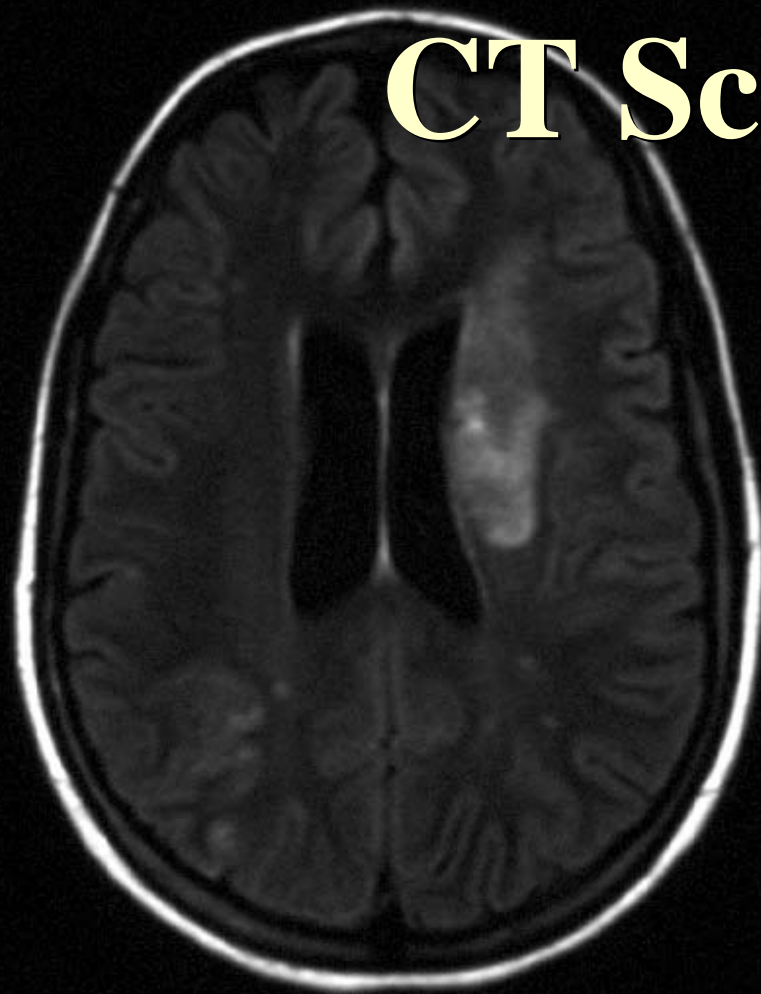
d

ardo Teaching

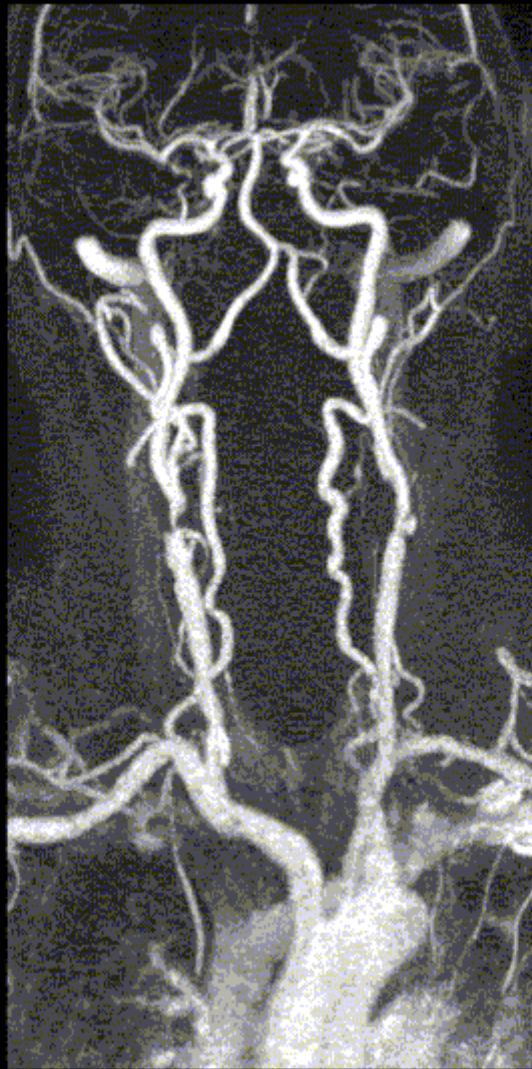Phoenix

et al.

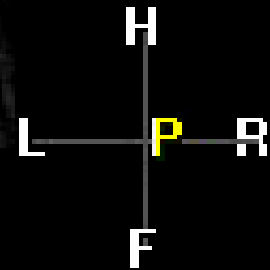
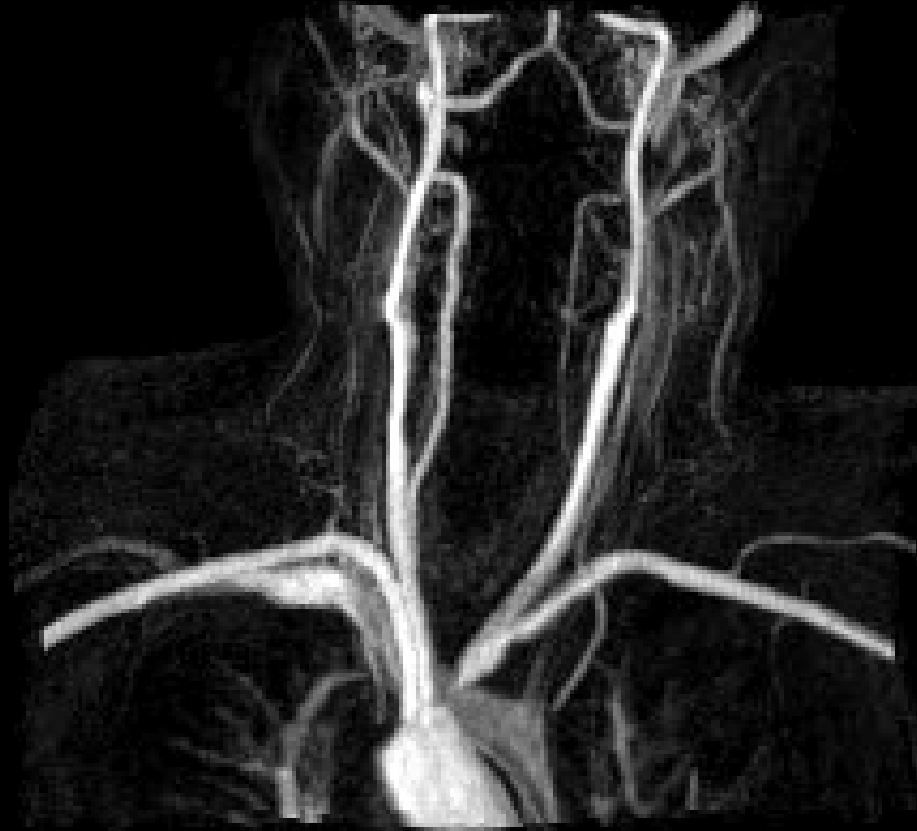# CT Scanning

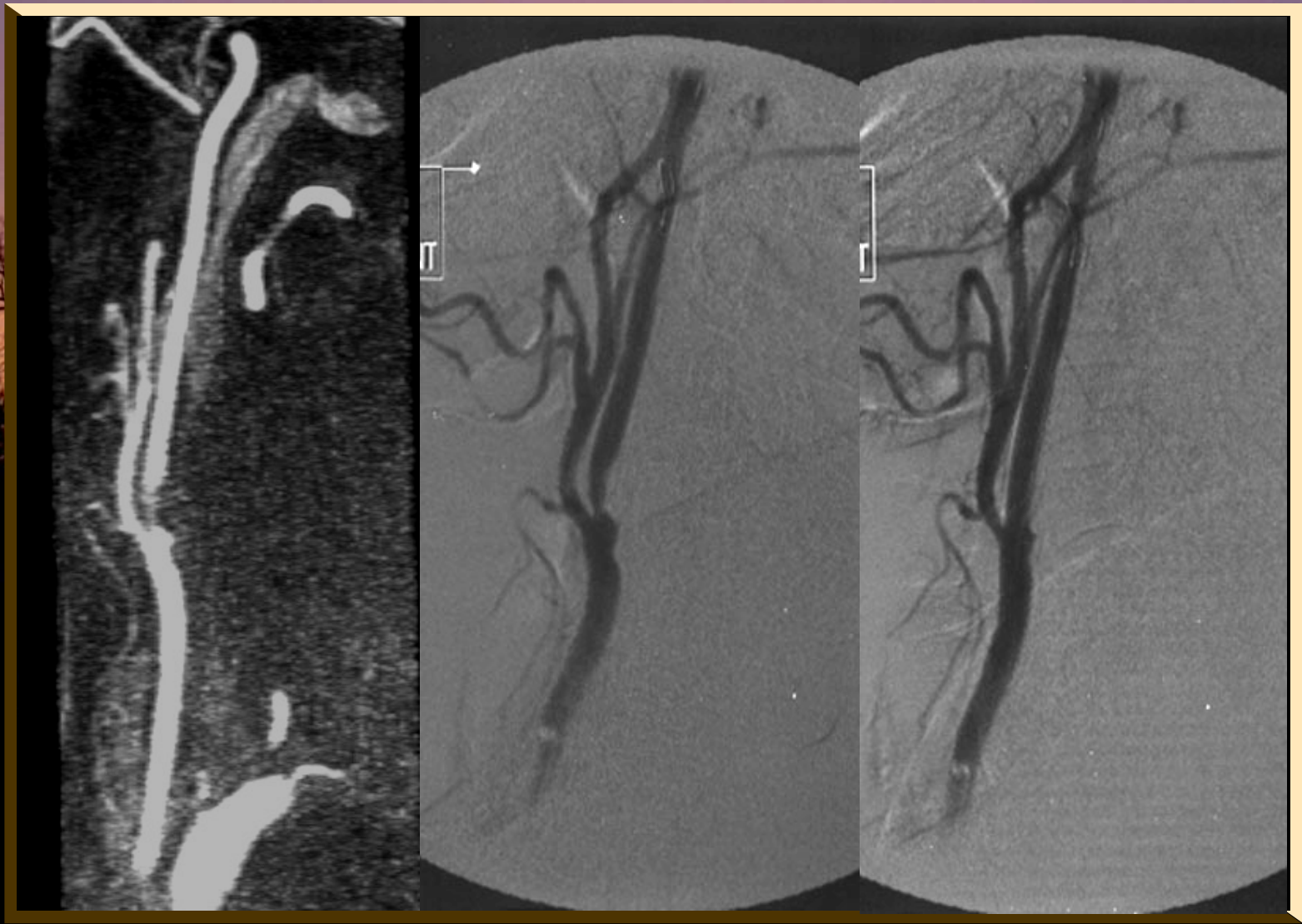

# MRA

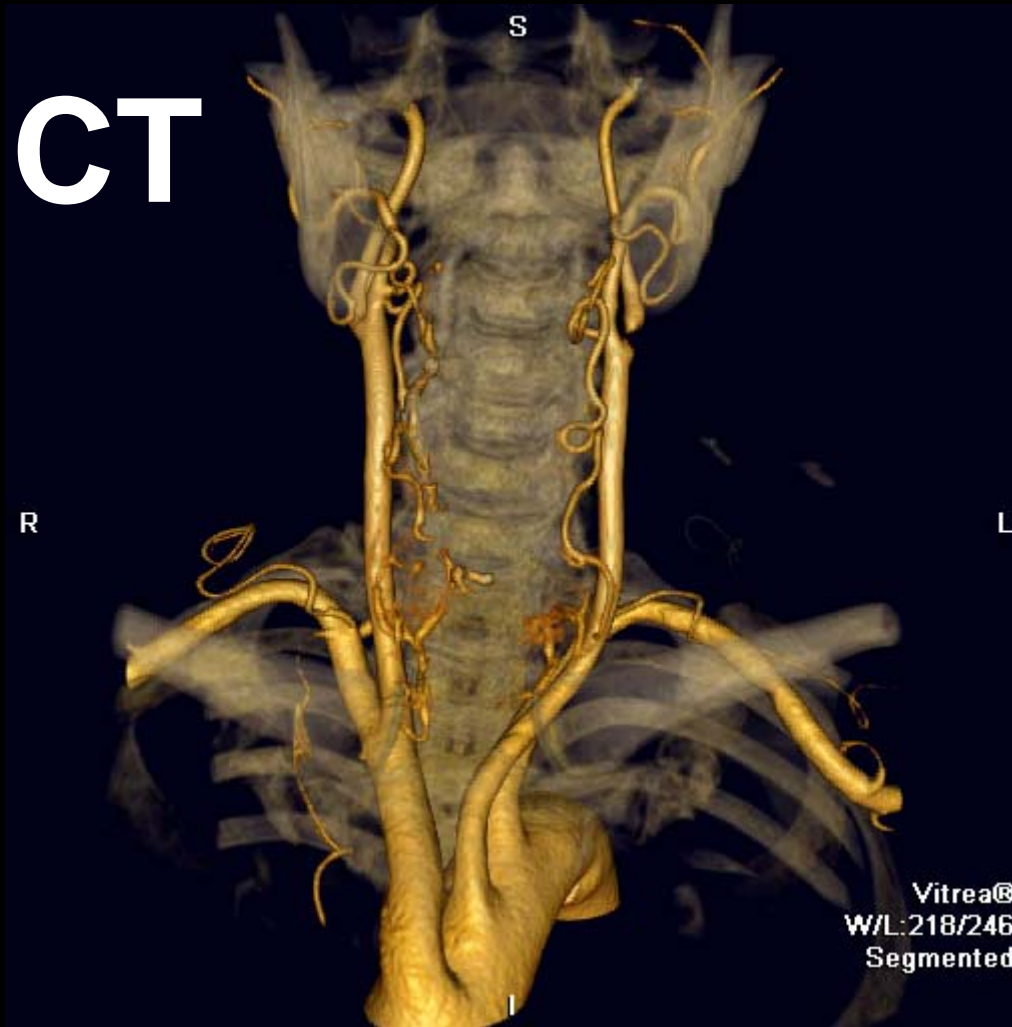


# MRA

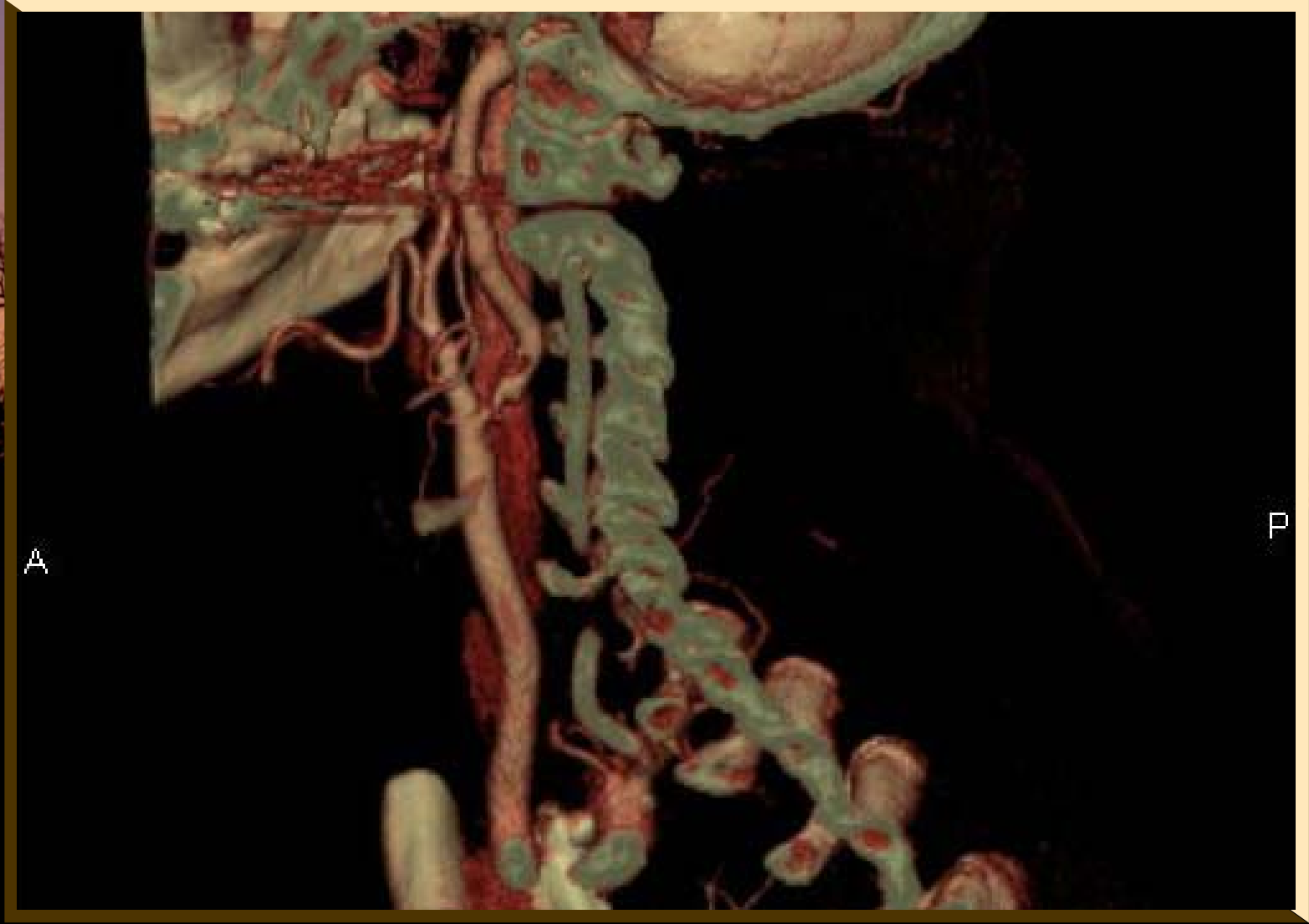




# 64 CT



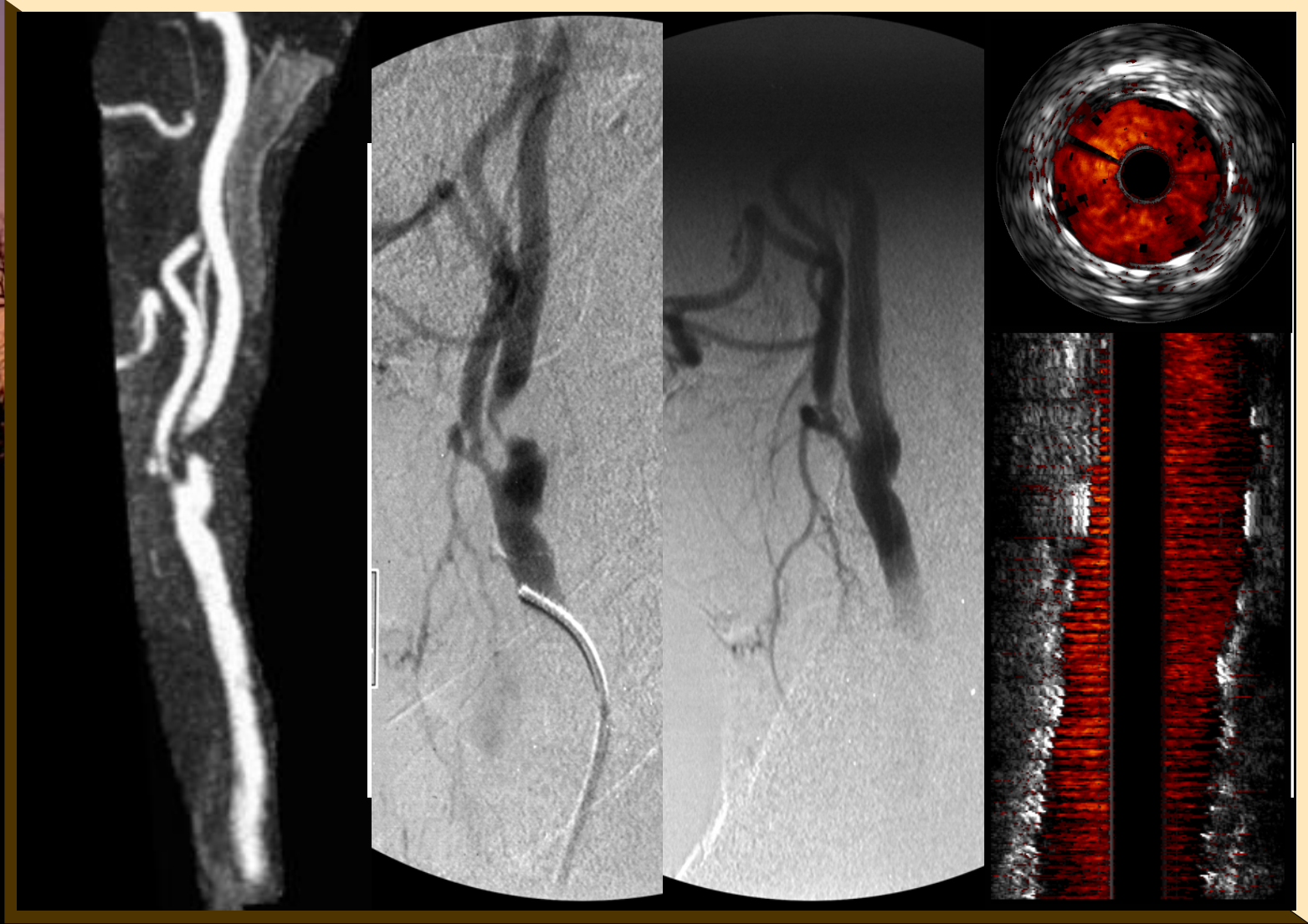




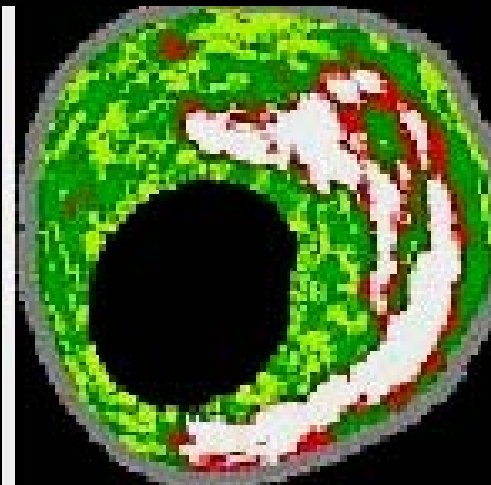
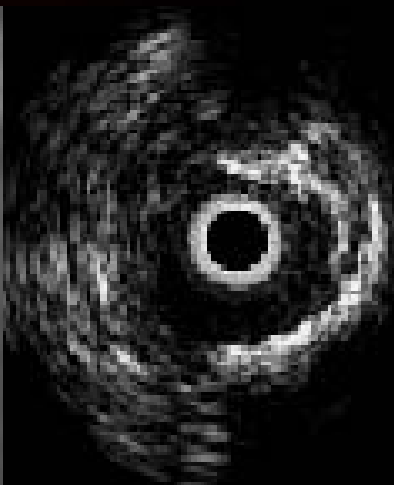
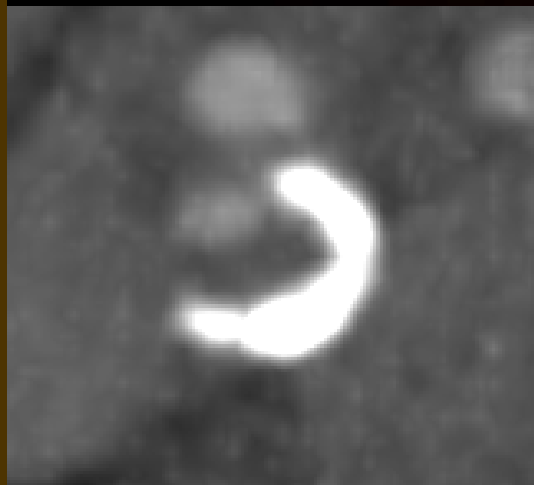A

P

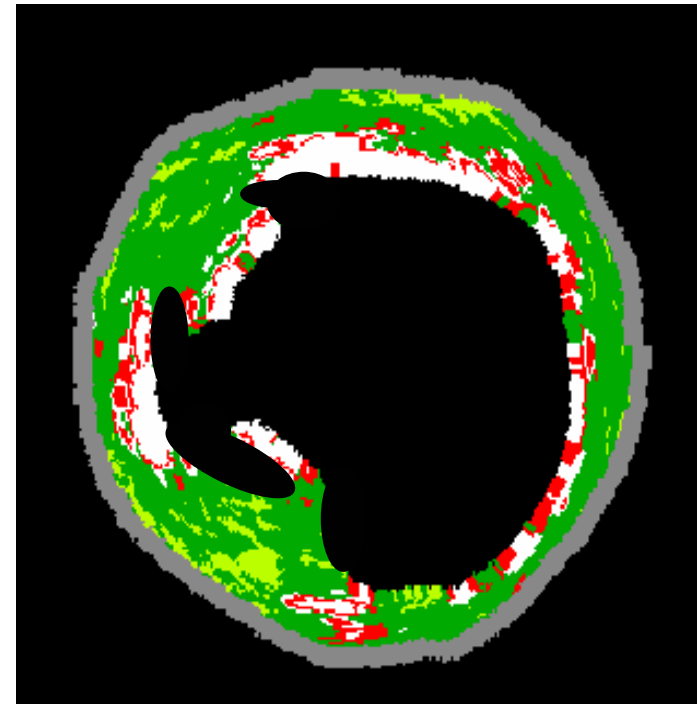
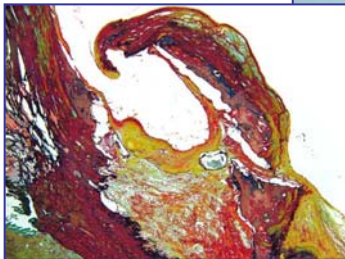
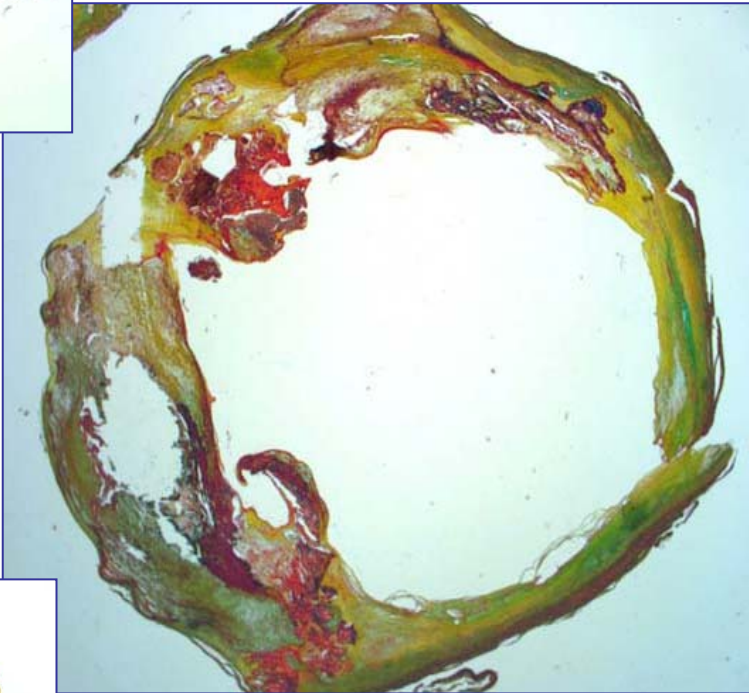
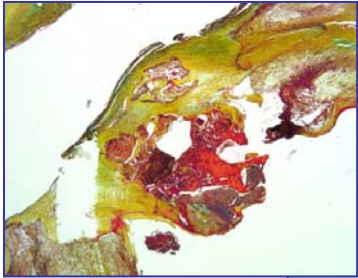




# IVUS



# VIRTUAL HISTOLOGY IVUS :CAPITAL STUDY



*Diethrich EB, Margolis PM, Reid DB et al.  
Endovasc Ther 2007 ; 14 : 676 - 686 .*

*J*

# Conclusions

